

Enfuvirtide administration in HIV-positive transgender patient with soft tissue augmentation: US evaluation

Eugenia Gabrielli¹, Giovanna Ferraioli², Lorenzia Ferraris¹, Agostino Riva¹,
Massimo Galli¹, Carlo Filice², Cristina Gervasoni¹

¹Clinical Science Department, Section of Infectious Diseases, University of Milan, L. Sacco Hospital, Milan, Italy;

²Division of Infectious and Tropical Diseases, IRCCS San Matteo, Pavia, Italy

SUMMARY

Enfuvirtide is a large protein that should be injected subcutaneously to ensure an appropriate absorption. Here we report the case of a transgender HIV-positive patient receiving enfuvirtide with an individualized background regimen of antiretroviral drugs, who had previously undergone liquid silicone oil injections. We performed US scan to detect silicone-free areas for following enfuvirtide injections. US can be useful in the correct management of those patients with liquid silicone oil soft tissue augmentation who require subcutaneously injected drugs.

KEY WORDS: Ultrasound, enfuvirtide, silicon oil

Received August 4, 2009

Accepted September 30, 2009

INTRODUCTION

Enfuvirtide (Fuzeon, Roche, Switzerland) was particularly useful in combined ARV regimens for patients harboring resistant HIV-1 strains. As it is the only ARV agent that acts as an entry inhibitor, its resistance profile is different and its use increases the genotypic sensitivity score, thus often making it part of the ARV regimens offered to patients experiencing virological failure. It shows also a good immunological profile, thus it is now considered a valid therapeutic option in immunological non-responders, and its use for three or six months in combination with an ongoing and efficient ARV regimen may improve CD4 cell counts (Bienvenu *et al.*, 2006; Clotet *et al.*, 2004). Enfuvirtide is a large protein that should be injected subcutaneously to ensure an

appropriate absorption. To reduce the rate of local injection site reactions, enfuvirtide should not to be injected into moles, scars, bruises or areas that could be irritated by a belt or waistband (Shalit *et al.*, 2007; Trottier *et al.*, 2005; Luther *et al.*, 2007).

In transgender HIV infected patients who are eligible to enfuvirtide treatment, care should be taken when choosing the injection site in case they had previously had liquid silicone oil injections for cosmetic applications or had sought surgical treatment for silicone implants.

We describe the case of a transgender HIV-positive patient, requiring enfuvirtide with an individualized background regimen of antiviral agents treatment, who had had liquid silicone oil injections years before.

CASE REPORT

AS, a 33-year old transgender HIV-positive patient was immunological non-responder to standard treatment and thus eligible for enfuvirtide treatment combined to optimal background therapy. He had undergone liquid silicone oil injection

Corresponding author

Cristina Gervasoni

Department of Clinical Science

Infectious Diseases Section

L. Sacco Hospital, University of Milan

G.B. Grassi, 74 Street - 20157 Milano

E-mail: cristina.gervasoni@unimi.it

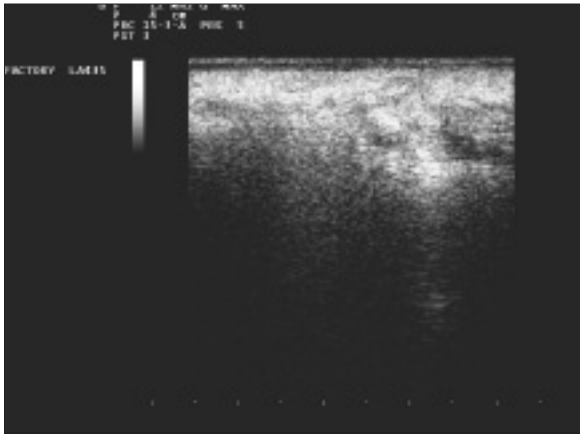


FIGURE 1 - US scan of the subcutaneous abdomen region performed with a 12 MHz linear array transducer shows the snowstorm pattern that obscures the posterior details of the area. This finding is consistent with the presence of silicone droplets.

tions in breasts - that were in part migrated in the abdomen, hips and buttocks- ten years earlier in San Paolo, Brazil.

Before the subcutaneous injection of the drug, in an attempt to avoid the side effects related to injection site reactions and allow an optimal absorption of enfuvirtide avoiding the silicone-filled areas, a systematic ultrasound (US) scan of the subcutaneous tissue was performed using a commercially available equipment (Esaote MyLab 50, Genoa, Italy) equipped with a high-resolution linear array transducer (12 MHz). The US scanning

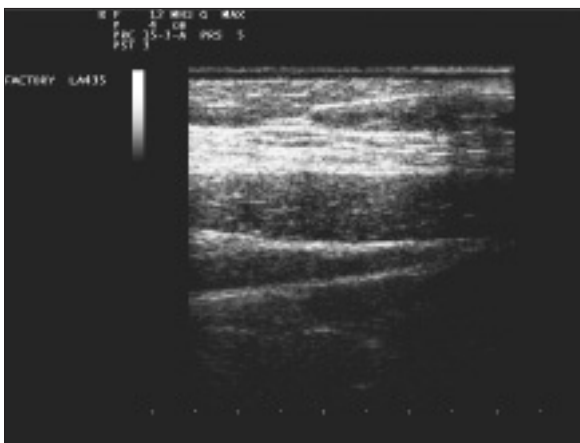


FIGURE 2 - US scan of the subcutaneous abdomen region performed with a 12 MHz linear array transducer shows the normal sonographic pattern of the cutaneous, subcutaneous and muscular planes.

was performed in a radial pattern, with images being acquired along the radial and anti-radial planes. The presence of silicone was identified when highly echogenic areas of scattered and reverberating echoes poorly defined on the posterior aspect with a snowstorm appearance as previously described (Harris *et al.*, 1993), where detected (Figure 1). The cutaneous, subcutaneous and muscular planes were correctly visualized in the silicone-free areas (Figure 2). The silicone-free areas were marked using a skin pencil to identify suitable sites for subsequent enfuvirtide injections. To validate our US scans, the same technique was tested in other three transgender patients who had undergone liquid silicone oil injections four, seven and eight years before. In all cases the silicone-containing areas showed a similar US pattern. After six months of follow-up, the enfuvirtide-treated patient did not show any local reaction other than those generally reported in the literature, in particular induration and erythema (Ball *et al.*, 2003). Moreover, we observed an increase of CD4 cell count - from 133 to 530 cell/mm³ - accounting for a proper absorption of the drug.

DISCUSSION

Local injection site reactions are the most common adverse event associated with enfuvirtide, but they are rarely treatment limiting. Only 4.4% of patients discontinued enfuvirtide over 48 weeks of treatment because of local reactions (Trottier *et al.*, 2005). There are no published data concerning the use of enfuvirtide in patients with liquid silicone oil injected for soft tissue augmentation.

As shown by several authors, US sensitively detects small amounts of free silicone, and echogenic noise when examining subcutaneous tissue is sufficient to indicate its presence (Roscullet *et al.*, 1992; Rubin *et al.*, 1994; Scaranelo *et al.*, 2006). Scaranelo *et al.*, 2006 have described four patterns of liquid silicone US presentation in subcutaneous tissues: macronodular, micronodular, mixed or snowstorm. This last form is the most common and it correlates with the phase US aberration caused by the sound waves passing through tiny silicone droplets, in which sound speed is slower (997 m/s) than in adjacent tissues (1540 m/s), thus leading to the

loss of sound beam coherence and “noise” (Rubin *et al.*, 1994).

Due to its availability, low costs, absence of ionizing exposure and compliance of patients, ultrasonography might be useful in managing correctly the increasing number of HIV transgender patients with liquid silicone oil soft tissue augmentation who are non-responders to standard ARV regimens.

REFERENCES

- BALL R.A., KINCHELOW T. (2003). Injection site reactions with the HIV-1 fusion inhibitor enfuvirtide. *J. Am. Acad. Dermatol.* **49**, 826-831.
- BIENVENU B., KRIVINE A., ROLLOT F., ET AL. (2006). A cohort study of enfuvirtide immunological and virological efficacy in clinical practice. *J. Med. Virol.* **78**, 1312-1317.
- CLOTET B., RAFFI F., COOPER D., ET AL. (2004). Clinical management of treatment-experienced, HIV-infected patients with the fusion inhibitor enfuvirtide: consensus recommendations. *AIDS.* **18**, 1137-1146.
- HARRIS K.M., GANOTTI M.A., SHESTAK K.C., LOSKEN H.W., TOBON H. (1993) Silicone implant rupture: detection with US. *Radiology.* **187**, 761-768.
- LUTHER J., GLESBY M.J. (2007). Dermatologic adverse effects of antiretroviral therapy: recognition and management. *Am. J. Clin. Dermatol.* **8**, 221-233.
- ROSCULET K.A., IKEDA D.M., FORREST M.E., ET AL. (1992). Ruptured gel-filled silicone breast implants: sonographic findings in 19 cases. *AJR Am. J. Roentgenol.* **159**, 711-716.
- RUBIN J.M., HELVIE M.A., ADLER R.S., IKEDA D. (1994). US appearance of ruptured silicone breast implants. *Radiology.* **190**, 583.
- SHALIT P., TRUE A., THOMMES J.A. (2007). Quality of life and tolerability after administration of enfuvirtide with a thin-walled needle: QUALITE Study. *HIV Clin. Trials.* **8**, 24-35.
- TROTTIER B., WALMSLEY S., REYNES J., ET AL. (2005). Safety of enfuvirtide in combination with an optimized background of antiretrovirals in treatment-experienced HIV-1-infected adults over 48 weeks. *J. Acquir. Immune Defic. Syndr.* **40**, 413-421.
- SCARANELO A.M., DE FÁTIMA RIBEIRO MAIA M. (2006). Sonographic and mammographic findings of breast liquid silicone injection. *J. Clin. Ultrasound.* **34**, 273-277.

